

# The indispensable use of CBCT in the posterior mandible

**Author:** Souheil Hussaini, Dubai

The **submandibular fossa (SF)** is an important anatomic landmark of the mandible, where the submandibular gland resides. During dental practice, particular attention is paid to SF when conducting the placement of dental implants and other surgical procedures. Any procedure undertaken has to be carried out with great care and attention in order to avoid perforation of this area. Anatomical variations of SF can occur, such as a deeply prominent and flat area with no depression. On very rare occasions, the mylohyoid ridge cannot be detected radiographically or bimanually as the observation of this variation is not always possible using a conventional radiograph. However, as a modern imaging resource, cone beam computed tomography (CBCT) allows an accurate three-dimensional assessment of SF as well as the identification of its degree of concavity.

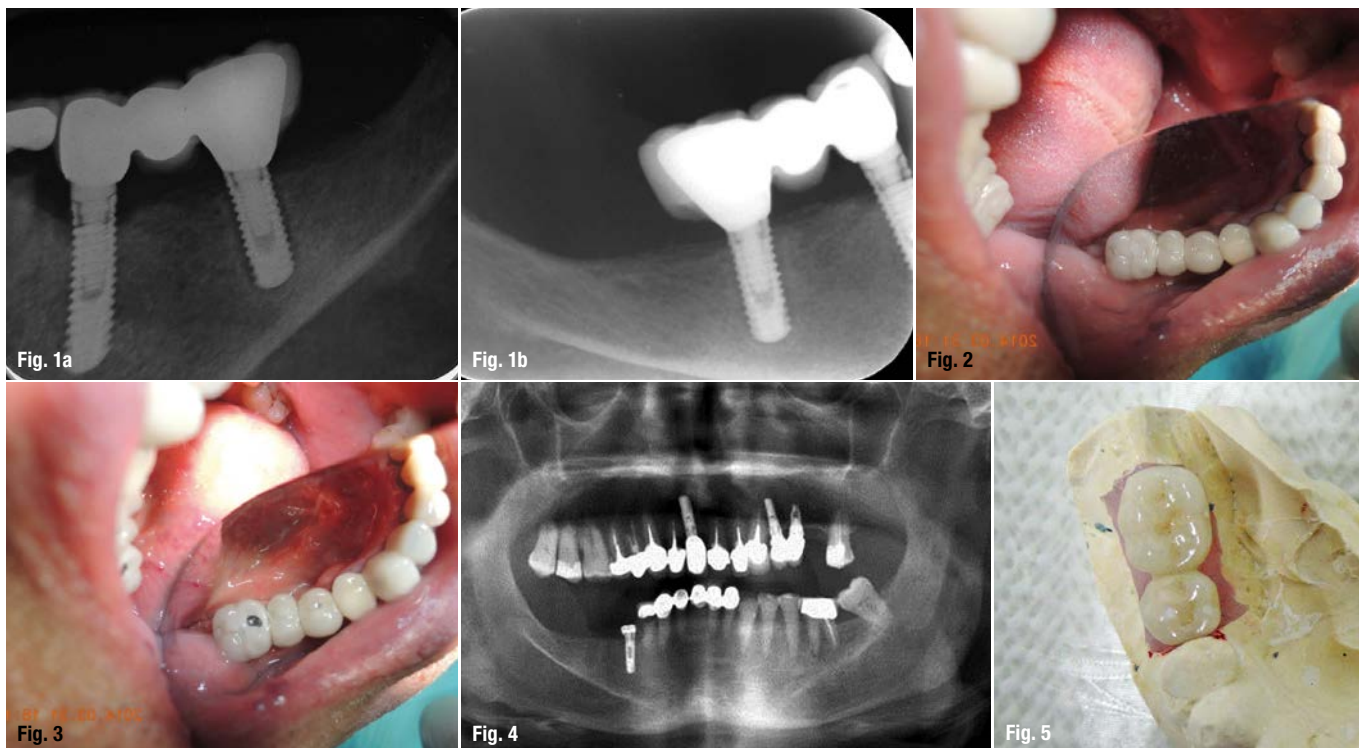
The aim of this article is to discuss the successful circumvention of SF as a result of CBCT images taken during the treatment of a 65-year-old non-smoking, healthy male. Primary implant stability required an implant length longer than the previously failed implant. A stable insertion of the implant between SF and the inferior alveolar nerve (IAN) was made possible by utilising CBCT. The patient presented no sensorial disturbance in the region and the treatment was considered successful 14 months after restoration.

Furthermore, this clinical case demonstrates the importance of 3-D imaging and its clinical necessity, as it enables the practitioner to reach a definitive diagnosis during treatment planning in spite of the patient's misleading complaint.

The submandibular fovea (or submandibular fossa or submaxillary fovea) is an impression on

the medial side of the body of the mandible below the mylohyoid line. It is the location for the submandibular gland.<sup>1</sup> Mandibles with lingual concavity pose a potentially increased risk of lingual cortical perforation during surgery, particularly with an endosseous implant placement. Cross-sectional imaging provides excellent delineation of mandibular anatomy and gives important information on the depth of the submandibular gland fossa during preoperative assessment of the posterior mandible for dental implant fixture placement and other surgical procedures.<sup>2,3</sup> Radiographically, SF can be seen as an undefined ovoid radiolucent area in both the right and left sides of the mandible. Conventional radiographs widely used in dental practice, such as periapical and panoramic, provide a two-dimensional (2-D) image of a three-dimensional (3-D) structure.<sup>4,5</sup> For this reason, SF may not be clearly visible in most cases, due to the superimposition of anatomic landmarks,<sup>5-8</sup> the pattern of trabecular bone,<sup>9</sup> the thinning of the mandible as well as the location below the mylohyoid line.<sup>5-7</sup>

Nowadays, CBCT represents an advanced technology in dental practice. This technology allows an accurate three-dimensional (3-D) evaluation of osseous structures in the maxillofacial region and makes it possible to assess SF in sagittal, axial, and coronal slices and to obtain detailed information concerning this anatomic landmark.<sup>5,7,8,10</sup> The importance of SF in dental practice, especially for dental implant placements and other surgical procedures in mandibular molar regions, is highlighted by the literature on this subject.<sup>2,3</sup> The detection of SF location and depth is important in order to avoid perforation, haemorrhage or asphyxia due to difficulty in breathing following suffocation.<sup>11</sup> In addition, an effective diagnostic radiographic technique of SF enables the practitioner to place an



implant between SF and the inferior alveolar nerve (IAN).<sup>2,3,5-7,9,10</sup>

### Case

This article discusses the unexpected findings that continuously emerged throughout the treatment process due to the absence of CBCT imaging in the initial phase of diagnosis, as well as the insufficiency of panoramic radiographic images in that clinical situation.

The patient's initial situation was characterised by a loose three-unit fixed partial denture, 45 implant supported, 46 pontic and 47 implant supported. Initially, the patient opposed the use of a radiograph and, as a consequence, the need for implant extraction was misdiagnosed. Eventually, in order to complete the extraction, all three types of common radiography techniques—periapical, panoramic and CBCT5—were needed and applied.<sup>5,7,10</sup>

The main complaint of the 65-year-old non-smoking male with no medical history or use of medication was "my bridge is moving and requires re-cementing". During an emergency appointment, the patient enquired about the costs for the re-cementing of a three-unit bridge. The patient presented a six-month-old periapical radiograph (Figs. 1a) while declining to take any further X-rays for a simple bridge re-cementing procedure. According to the patient, the implants

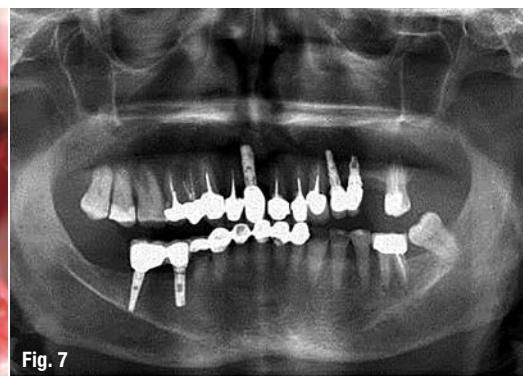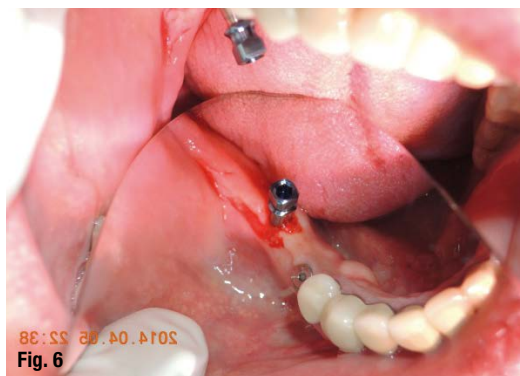were placed five years ago and without incision by a now-retired dentist who could no longer be contacted. After analysing the radiograph and making a clinical assessment, the provisional diagnosis showed that the bridge was moving due to an abutment screw loosening (Fig. 2). The resulting treatment plan called for the removal of the three-unit bridge and the re-tightening of the abutment screw to the manufacturers recommended preload as well as the re-cementing of the bridge (plan A).

The patient approved the suggested procedures and signed the treatment plan. The bridge was found to be firmly attached to the anterior implant and loosely connected to the posterior one. The existing bridge had to be cut out and replaced by a new three-unit bridge (plan B). A small opening of the screw access hole was attempted on both implant restorations 45 and 47 (Fig. 3). Although the access hole did not lead to the abutment screw, the bridge mobility was increased. A periapical radiograph was obtained to evaluate the peri-implant status of the posterior implant (Fig. 1b). The radiolucency observed around the fixture indicated implant failure and the crown in the anterior implant had to be sacrificed in order to get to its abutment safely. At this stage (plan C), the procedures were set out as follows: removal of the posterior implant followed by a re-implant, a new temporary crown on tooth 45 and, after two months, fitting of a two-unit bridge instead of the previous three-unit bridge restoration. This deci-

**Fig. 1a:** Periapical radiograph.  
**Fig. 1b:** Digital periapical radiograph.  
**Fig. 2:** Occlusal view of the bridge.  
**Fig. 3:** Occlusal view after attempting to get to the abutment.  
**Fig. 4:** Panoramic radiograph, diagnosis.  
**Fig. 5:** Occlusal view of PFM bridge.

**Fig. 6:** Re-implant placed flapless.

**Fig. 7:** Panoramic radiograph, restoration



sion resulted from the fact that the mesio-distal length of the bridge required to accommodate three teeth was 18 mm and not 21 mm.

The height of the extracted implant and the available bone was 8 mm when the panoramic image was evaluated (Fig. 4). As the available diagnosis information did not provide data regarding the desired diameter and angulation of the implant to be placed, the patient's consent for CBCT (plan D) was obtained and added to the contractual treatment plan. Only then, the radiograph of the molar region of the right mandible was performed. CBCT (Planmeca ProMax 3D s, Planmeca Oy, Helsinki, Finland, Table 1) and the measurements in millimeters of the bone height and angulation using tools of the Planmeca software (Romexis 2.5.1.R), in the most representative CBCT transversal slice demonstrated the possibility of placing a 13 mm implant (853213 – 3.2mmD, 13mmL Implant Direct Legacy3, Implant Direct, CA, USA) with 35 degree lingual angulation to avoid SF (Fig. 5).

### Treatment timeline

The timeline detailing the entire treatment was as follows:

- 31 March 2014 Diagnosis and treatment planning

- 2 April 2014 quality control (QC) phone call with no patient response, possibly due to disappointment over many changes in treatment plan
- 6 April 2014 implant placement 3.2 x 13 mm implant direct (Fig. 6),
- 15 April 2014 QC with positive response,
- 14 June 2014 uncovering and impression using open tray technique,
- 17 June 2014 QC with positive response,
- 21 June 2014 prosthesis 2 unit bridge PFM cemented with Temp Bond (Fig. 7),
- post-operative one-year maintenance visit on 10 August 2015 showed healthy functional results as recorded (Fig. 8).

### Analysis of patient images

1. Axial CBCT slice in which the angle required (35 degree) to bypass SF corresponding to longest necessary length (13 mm) and diameter (3.2 mm) was measured (Fig. 9).
2. Coronal CBCT slice in which the openings corresponding to the lingual 1.9 mm and buccal 2.5 mm bone thickness, was measured respectively (Fig. 10).
3. Transversal CBCT image from lingual wall demonstrating the severe SF depression (Fig. 11).
4. Axial CBCT slice shows the height of the extraction socket as 8 mm (Fig. 12).

Panoramic radiography, in which images of the right and the left inferior alveolar nerves are clearly seen below the opaque mylohyoid line, demonstrate that the right and the left SFs are seen as clear radiolucent areas, with the IAN giving the illusion of sufficient length to place a regular size implant.

### Discussion

The use of a wider diameter implant with the same height was the alternative solution if CBCT was not available. CBCT occlusal images (Fig. 10) indicated that a wider implant diameter would have destroyed the lingual plate of the bone in that area.<sup>12</sup> The surgery was performed without raising

**Table 1:** Technical data.

Anode voltage	60–90 kV
Anode current	1–14 mA
Focal spot	0.5 mm, fixed anode
Image detector	Flat panel
Image acquisition	Single 200 degree rotation
Scan time	7.5–27 s
Reconstruction time	2–25 s

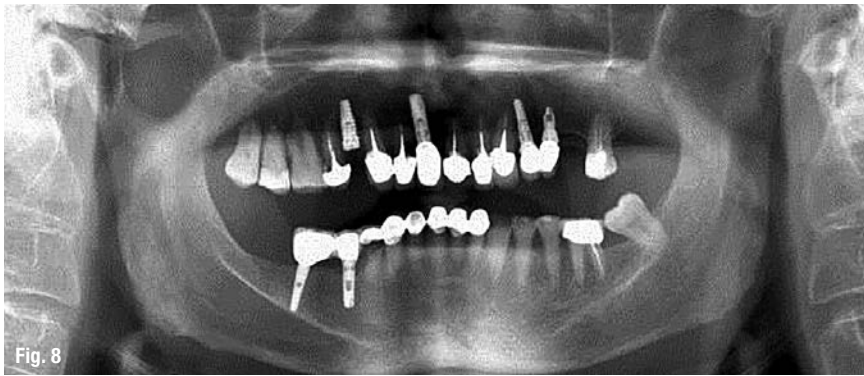


Fig. 8

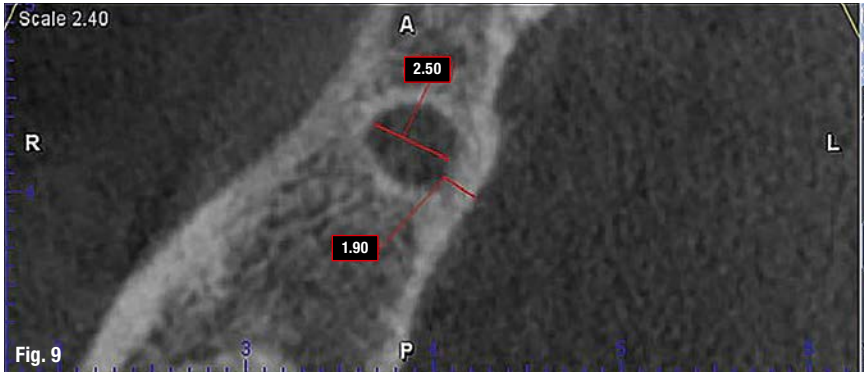


Fig. 9

**Fig. 8:** Panoramic radiograph, one-year post-op.

**Fig. 9:** Bone width lingual wall 1.9mm and buccal 2.5mm.

a flap for better post-operative healing.<sup>13</sup> Traditionally, we do not require CBCT images for a single implant placement.<sup>14</sup> However, this case signifies the importance of 3-D imaging in certain situations like deep SF (Fig. 11).

When the bone width is narrow, periosteal elevation is recommended to be able to safely observe the osteotomic drills as they reach to the final depth. This procedure is only advised when a panoramic image is the only diagnostic tool we have as it adversely causes further bone loss during the healing phase.<sup>13</sup> In the present case, no periosteal elevation was performed (Fig. 6) and the patient did not have post-operative pain and swelling.

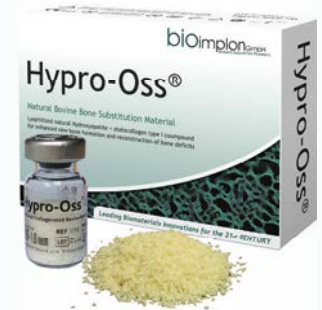CBCT is a modern technology, which allows the three-dimensional evaluation (sagittal, axial and coronal) of maxillofacial structures. Among its many advantages are the absence of superimposition of structures in obtained slices, acquisition of a 3-D reconstruction (spatial vision for illustrative purpose), as well as the use of lower radiation doses in comparison to medical CT.<sup>15-17</sup> SF location, size, shape and its possible variations can be fully as-

essed by CBCT.<sup>2,3,18-22</sup> Due to the limitations of periapical and panoramic techniques, the radiographic assessment of SF is not always available. Jacobs et al. reported that SF was detected in 94% of their assessed panoramic radiographs, but only 49% of those were clearly visible.<sup>23-25</sup> Therefore, it can be reasonably concluded that the lack of observation of SF in conventional radiograph does not prove its actual absence.

In our reported case, we were able to evaluate the mandible of the patients in 3-D and here SFs were actually deeply prominent and hypoplastic. Also, it was impossible to perform the surgery without 3-D imaging. A preoperative imaging study is important prior to any surgical procedure in the posterior mandibular region.<sup>2,8</sup> CBCT can be very helpful for the detection of SF variations that could be otherwise missed using conventional radiographic examination techniques.<sup>2,5,7,10</sup> In the present case, the diagnosis of the anatomic limitation was possible to be visualised due to CBCT examination. Furthermore, the accurate measurements of SF and the vision of 3-D spatial reconstructions, which are exclusive tools of

## Hypro-Oss®

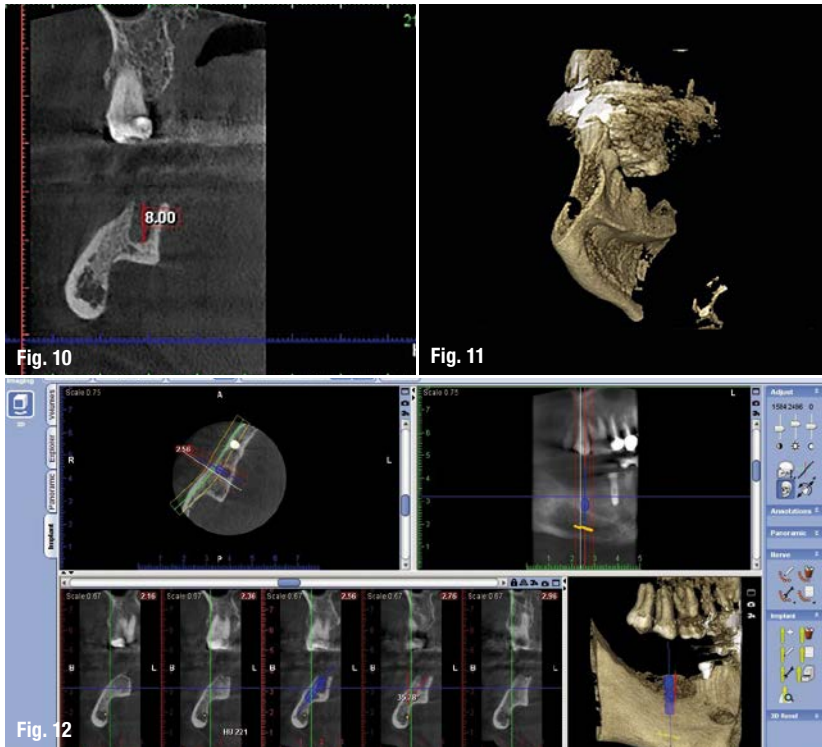
the revolutionary  
bovine bone graft  
composite



- ✓ each granule is a composite of 30% Atelo-Collagen Type I, 70% hydroxyapatite
- ✓ atelo-peptidized, free of antigenic telopeptides
- ✓ natural crystalline structure of hydroxyapatite component
- ✓ bioactive growth factors
- ✓ haemostatic and bacteriostatic properties
- ✓ no need for steroids as anti-haematoma medication
- ✓ highest quality of new bone formation
- ✓ conductive and inductive properties
- ✓ excellent handling due to sticky Atelo-Collagen components

**bioimplon** GmbH  
Biotech Innovation Pioneers

Bioimplon GmbH  
Friedrich-List-Str. 27  
35398 Gießen  
+49 (0)641 6868 1123  
www.bioimplon.de



**Fig. 10:** Axial CBCT slice demonstrates the height of the extraction socket is 8 mm

**Fig. 11:** Deep SF.

**Fig. 12:** CBCT images providing a virtual implant position and angulation.

computed tomography technology, bring advances to the study of the anatomic landmarks. Several authors emphasise how implant placement has been improved by using preoperative CTs for the success of surgical treatments. Precise 3-D visualisation of the edentulous area and consequently the insertion of the implant can be obtained through the use of CBCT imaging, facilitating computer-assisted planning of oral implant surgery.<sup>6,10,21,26</sup>

Even though, the technology of cone beam computed tomography is rapidly improving, the benefits of a CBCT investigation must outweigh any potential risks.<sup>4,5,27,28</sup>

Based on one hundred spiral computed tomographic (CT) preoperative examinations of patients requiring assessment of the lower jaw, before implant placement samples, Parnia F et al. classified the depth of the submandibular gland fossa as a function of the lingual concavity depth over a range of up to a maximum value of 6.6 mm.<sup>2</sup> Mandibular lingual concavity depth was divided into three groups. A lingual concavity (depth  $\geq 2$  mm) was observed in 80% of the jaws. In 20% of the cases, there were flat depressions less than 2 mm in depth (Type I) and in 52% of the cases the concavities were two to three mm deep (Type II). About 28% of the examined regions showed significant concavities of more than three mm (Type III). The obtained distribution did not reveal any dependence on age and gender of the patients examined

in this study ( $P > .05$ ). Kobayashi et al. found that measurement errors ranged from 0 to 1.11 mm (0% to 6.9%) on CT and from 0.01 to 0.65 mm (0.1% to 5.2%) on CBCT, with measurement errors of 2.2% and 1.4%, respectively ( $P .0001$ ).<sup>29</sup> Based on those results, this study suggests that distance can be measured accurately by using CBCT. Lascaia et al. concluded in their study that, although CBCT image underestimates the actual distances between skull sites, differences are only significant for the skull base and therefore it is reliable for linear evaluation measurements of other structures more closely associated with dentomaxillofacial imaging.<sup>30</sup>

According to Chan HL et al. the incidence of lingual plate perforation during implant placement is predicted to be 1.1% to 1.2% and will most likely happen in type-U ridge.<sup>3</sup>

### Conclusion

Images acquired using two-dimension (height and width) radiography cannot reveal valuable information in third-dimension (depth). This fact limits its use. In certain situations, for example deep SF for implant selection, three-dimensional visualisation of the anatomical limitation is desirable. In those circumstances, three-dimensional imaging provided by CBCT is extremely valuable. In comparison to panoramic radiograph, the use of CBCT can greatly improve the visualisation leading to a more definitive diagnosis and the best possible treatment plan.

*The author declares no conflict of interest.*

*Editorial note: A list of references is available from the publisher.*

### Contact

**Dr Souheil R. Hussaini, BDS, MS**  
 Oral Implantology Medical Center  
 204 Al Wahda Building, Port Saeed Rd, Deira,  
 P O Box 39695 Dubai, UAE  
 Tel.: +971 4 2956595  
 Fax: +971 4 2958757  
 souheilh@eim.ae  
 www.ID-SC.com